

Forestier disease associated with a retroodontoid mass causing cervicomedullary compression

NARESH P. PATEL, M.D., NEILL M. WRIGHT, M.D., WILLIAM W. CHOI, M.D.,
DUNCAN Q. MCBRIDE, M.D., AND J. PATRICK JOHNSON, M.D.

Comprehensive Spine Center, Division of Neurosurgery, UCLA Medical Center; and Institute for Spinal Disorders, Cedars-Sinai Medical Center, Los Angeles, California

Object. Forestier Disease (FD) is a progressive skeletal disorder affecting predominantly older men. It is also known as diffuse idiopathic skeletal hyperostosis (DISH) and is characterized by massive anterior longitudinal ligament calcification that forms a bridge on the anterior border of the thoracic and subaxial cervical spine. To the authors' knowledge, retroodontoid masses associated with FD have not been described.

Methods. Five patients with FD and multilevel subaxial cervical fusion were treated for retroodontoid masses and cervicomedullary junction (CMJ) compression. There were four men and one woman (mean age 73 years, range 54–86 years). All patients suffered progressive neurological symptoms resulting from anterior compression of the CMJ.

Four patients underwent combined transoral resection of the ligamentous mass followed by an occipitocervical fusion procedure. One patient with circumferential CMJ compression underwent a posterior decompression and occipitocervical fusion. Histopathological examination of the mass showed hypertrophic degenerative fibrocartilage. Early postoperative neurological improvement was noted in all patients. The follow-up period ranged from 4 to 19 months. At the end of the follow-up period, four patients experienced neurological improvement. One patient died 3 weeks postsurgery of pulmonary complications.

Conclusions. The osseous elements of the occipitoatlantoaxial complex are not directly affected by FD. The ligamentous structures of the odontoid process, however, are exposed to significantly altered biomechanics resulting from fusion of the subaxial cervical spine associated with FD. Stress-induced compensatory ligamentous hypertrophic changes at the craniovertebral junction cause CMJ compression and subsequent neurological deterioration. This previously undescribed entity should be considered in patients with FD or DISH who present with progressive quadriplegia. Transoral decompression and posterior fusion are often needed in patients with large masses and severe progressive neurological deficits. Selected patients with smaller masses and milder neurological symptoms may be treated with posterior fusion alone.

KEY WORDS • Forestier disease • retroodontoid mass • cervicomedullary compression • diffuse idiopathic skeletal hyperostosis

FORESTIER disease, also known as DISH^{22,23} and occasionally as hyperostotic spondylosis and ankylosing hyperostosis, was originally described in 1950 by Forestier and Rotes-Querol.⁸ They coined the term “ankylosing hyperostosis of the spine” to describe a spectrum of rheumatological disorders found in the elderly population, especially men in their sixth to seventh decade of life. This disorder classically involves marked calcification of the ALL and absence of other degenerative changes.

They described the condition as “usually painless, and therefore latent.” The disease process has several different presentations, however. The most common presenting symptoms of cervical FD are dysphagia and, less frequently, dyspnea, resulting from local mechanical compression of the esophagus and trachea.^{7,10,11} In the rare re-

ported cases of FD associated with significant neurological deficit, the deficit is usually due to focal cervical and thoracic spinal canal stenosis.^{12,21,24} The extradural compression occurs secondary to focal fibrous proliferation of the ligamentum flavum, the origin of which is unclear.

Common causes of anterior CVJ compression include RA, Klippel–Feil syndrome, pseudogout, and basilar invagination.^{1,4,17,19,20,27,29} Although the pathophysiology of FD is unclear, it is not known to be associated with conditions that could cause such compression. To our knowledge, severe ligamentous hypertrophy and odontoid region pannus formation causing cervicomedullary compression has not been described in FD patients. In this report we discuss five patients with FD and retroodontoid masses and describe the pathophysiology of the mass formation and the treatment of this uncommon condition.

Clinical Material and Methods

Patient Population

During the 2-year period between 1995 and 1997, five

Abbreviations used in this paper: ALL = anterior longitudinal ligament; ASIA = American Spinal Injury Association; CT = computerized tomography; CVJ = craniovertebral junction; DDD = degenerative disc disease; DISH = diffuse idiopathic skeletal hyperostosis; FD = Forestier disease; MR = magnetic resonance; RA = rheumatoid arthritis.

Forestier disease and retroorbital mass

patients with FD were evaluated for CVJ compression symptoms in the Comprehensive Spine Center at the University of California, Los Angeles. There was no coexisting significant rheumatological, posttraumatic, or degenerative disease processes. A detailed retrospective evaluation of the medical records and radiological studies was performed. Characteristics in all patients fit the classic description of FD, although one patient with focal C4–5 DDD is included because no other sites of significant DDD were present. There were four men and one woman (mean age 73 years, range 54–86 years). A history of osteoarthritis of the bilateral lower extremities was noted in one patient.

Presenting Symptoms and Signs

All five patients suffered from significant neurological deficits when initially assessed. The majority of the patients exhibited myelopathic symptoms including hyperreflexia, spasticity, and a positive Babinski sign. To define the degree of disability, each patient was classified using the ASIA impairment scale (Table 1).^{6,28}

Diagnostic Investigation

All five of these elderly patients underwent a detailed medical evaluation preoperatively with focus on nutritional status, as well as on their respiratory and cardiac status. Preoperative and postoperative swallowing evaluation with a modified barium swallow was performed. Preoperative swallowing tests demonstrated abnormal status in two cases, one of which improved after surgery (Table 2). Additionally patients underwent preoperative evoked potential testing and intraoperative monitoring. Imaging studies included plain radiography, CT scanning, and MR imaging of the affected areas. The radiological criteria defined by Resnick and Niwayama^{22,23} for FD was used in the assessment of this group. A retroodontoid soft-tissue mass expanding into the canal and causing significant stenosis of the CVJ was present in all patients.

Results

Clinical Presentation

The most prominent complaints were gait disturbance, weakness, and paresthesias in the extremities (Table 3). Only one patient complained of difficulty in swallowing. One patient who experienced urinary frequency and urgency was determined to have prostatic hypertrophy. The usual symptoms of pain and stiffness of the middle and lower back were not present in our patients, although neck and extremity pain was prominent (Table 3). The duration of the symptoms ranged from 6 months to 5 years. The progression of gait disturbance and weakness, however, had a recent and rapid course, with four of five patients developing debilitating weakness within 6 to 8 months of onset. Three patients were classified with ASIA Grade C and two patients with Grade D impairment (Table 2).

Radiological Findings

The degree of spinal stenosis at the level of CVJ was severe in all patients (Table 4). There was no correlation between the degree of stenosis and the severity of symptoms. In all patients ALL ossification was noted between

TABLE 1
Summary of the ASIA impairment grading scale

ASIA Grade	Definition
A	complete: no motor or sensory function preserved in the S4–5 segments
B	incomplete: sensory but no motor function preserved below the affected level & extending through the S4–5 segments
C	incomplete: motor function preserved below the affected level, & the majority of key muscles below the affected level are < grade 3/5
D	incomplete: motor function preserved below the affected level, & the majority of key muscles below the affected level are ≥ grade 3/5
E	normal: motor & sensory function normal

C-3 and C-7 (Fig. 1 *upper left*). The most cephalad extent was the inferior aspect of C-2 in two patients. The mean ossified ALL was approximately 1 cm in thickness and caused anterior displacement of the prevertebral soft tissue. Involvement of another spinal region (T8–11) was present in only one patient. On plain radiographs and CT scans small areas of calcification were demonstrated within a defined retroodontoid mass (Fig. 1 *lower*). There was no osseous erosion of the atlantoaxial complex, and the gross osseous anatomy was relatively normal. The MR imaging studies revealed a soft-tissue retroodontoid mass that was slightly hypointense to neural matter on T₁-weighted sequences and areas of hypo- and hyperintensity on T₂-weighted sequences (Fig. 1 *upper right*). The degree of CVJ stenosis was significant (mean diameter 5 mm, range 4–7 mm) (Table 4). Imaging studies obtained in all patients revealed signs of myelomalacia with signal change in the cord on T₂-weighted MR images. There was fair but inhomogeneous contrast enhancement after intravenous gadolinium administration. Additionally in one patient there was radiographic evidence of basilar invagination, accentuating the degree of CVJ compression.

Surgical Procedure

During surgical decompression and stabilization, all patients underwent intraoperative sensory evoked potential monitoring. A transoral odontoidectomy and resection of the hypertrophic mass were performed in four patients. Three of four patients also underwent a posterior fusion procedure as an immediate second-stage procedure on the same day to stabilize the cervical spine (Fig. 2). One patient (Case 3) with associated basilar invagination required a transoral, transpalatal approach to obtain enhanced superior exposure. One patient (Case 1) underwent a posterior C1–2 fusion following a transoral decompression; this procedure was converted to an occiput–C3 fusion after dislodgment of the graft following a fall 1 month after the initial surgery. One patient (Case 4) in whom a stand-alone transoral decompression was initially performed underwent a delayed C1–2 fusion after developing a C1–2 subluxation with retrolisthesis and neurological deterioration. Another patient (Case 2) with an unusual circumferential compression and predominantly posterior column symptoms underwent a posterior decompression combined with an occiput–C4 fusion (Table 2).

TABLE 2
Summary of pre- and postoperative data in five patients with FD and a retroodontoid mass

Case No.	Age (yrs), Sex	Symptoms & Signs	Preop ASIA Grade	Investigation	Op Procedure	Complication	Pathological Finding	Outcome	Postop ASIA Grade
1	65, M	lt UE weakness: 4-/5 & numbness; bilat LE weakness: 4/5	D	MRI: ALL calcification, retro-odontoid mass, CVJ comp	transoral mass resection, pos C1-2 fusion: transarticular screw & Songer cable & ICBG	dislodged graft after falling; revision: Oc-C3 fusion	DFIP	improved strength: UE: 5/5; LE: 4+/5	D
2	75, F	prog weakness lt side: 3-/5; numbness hands & feet; paresthesia lt side for 6 mos	C	MRI: ALL calcification, retro-odontoid mass, CVJ comp, C3-4 DDD	pos decomp, Oc-C4 fusion: Steinmann pins & Songer cables	none	no specimen	improved strength: UE: 4+/5; LE: 4+/5	D
3	54, M	neck pain for 5 yrs; UE weakness: 2 to 3-/5; LE weakness: 3-/5 & paresthesia; dysphagia	C	MRI: ALL calcification, retro-odontoid mass, basilar invagination, CVJ comp; AbN swallowing test	transoral mass resection, Oc-C5 fusion: Steinmann pins & Songer cables	none	DFIP	improved strength: UE: 4+ to 5-/5; LE: 5-/5	D
4	84, M	prog gait instability for 8 mos; quadriparesis: 2 to 3-/5 LE paresthesia	C	MRI: ALL calcification, retro-odontoid mass, CVJ comp	transoral mass resection, PEG for postop feeding	retrolisthesis of C-1 on C-2, pos C1-2 fusion (Gallie), pneumonia	DFIP	improved strength: UE & LE: 3+/5; died 3 wks postop	D
5	86, M	prog quadriparesis: UE: 3+/5 & LE: 4/5; bilat hand numbness, neck pain	D	MRI: ALL calcification, retro-odontoid mass, CVJ comp; AbN swallowing test	transoral mass resection, Oc-C4 fusion: Steinmann pins & Songer cables	pneumonia	DFIP	improved strength: UE: 4+ to 5-/5 LE: 4+/5; improved swallowing	D

* AbN = abnormal; comp = compression; decomp = decompression; DFIP = degenerative fibrocartilagenous inflammatory process; ICBG = iliac crest bone graft; LE = lower extremity; MRI = MR imaging; Oc = occiput; PEG = percutaneous endoscopic gastrostomy; pos = posterior; prog = progressive; UE = upper extremity.

TABLE 3
Presenting signs and symptoms

Symptoms/Signs	No. of Patients (%)
gait disturbance	5 (100)
weakness	5 (100)
UE	5 (100)
LE	5 (100)
paresthesias	5 (100)
UE	3 (60)
LE	3 (60)
pain	4 (80)
cervical spine	2 (40)
UE	2 (40)
LE	3 (60)
dysphagia	1 (20)

Pathological Examination

Four patients underwent resection of the retroodontoid mass. Pathological specimens were examined both grossly and microscopically. The gross examination of the specimen showed pink to yellowish soft tissue. There were areas with a tan hemorrhagic component within the fibrous tissue. Microscopic examination showed similar pathological changes in varying degree in the material resected in the four patients. Such material would include the hypertrophic abnormal tissue found on the posterior aspect of the odontoid process, portions of the transverse/cruciate ligament, and portions of the odontoid itself. Portions of normal-appearing fibro- and hyaline cartilage were commonly found with a variable amount of normal adipose tissue and ligamentous material. In cases in which the odontoid processes were examined, unremarkable-appearing bone was demonstrated with modest endosteal fibrosis without hematopoiesis.

Significant pathological changes included fibrillation of fibro- or hyaline cartilage, loss of basophilia, and prominent zones of acellular eosinophilic degeneration (Table 2). Such zones may be very small areas surrounded by normal cellular cartilage but grow by confluence of contiguous areas to reach significant size. Multifocal zones of chondrocyte hyperplasia were observed. Such foci often bordered areas of chondroid fibrillation or acellular eosinophilic degeneration. Elsewhere, focal neovascularization was observed, occasionally accompanied by modest chronic inflammation and fibrosis. These zones were reminiscent of mature granulation tissue. Granular calcification or, rarely, dystrophic ossification was noted in the zones of acellular eosinophilic degeneration. None of the specimens had pyrophosphate dihydrate crystal deposit.

Procedure-Related Outcome

Neurological improvement was demonstrated in all patients immediately postoperatively, with an increase of approximately one ASIA grade in motor strength demonstrated in three patients within 2 weeks. Complications included aspiration pneumonia in two patients and graft dislodgment in the patient who underwent a C1–2 fusion. In the patient who did not undergo an immediate posterior stabilization procedure a C1–2 subluxation developed 1 week after surgery. A posterior C1–2 fusion was performed, but the patient eventually died of pulmonary com-

TABLE 4
Radiographic findings

Case No.	Anteroposterior		Coexisting Spinal Abnormality	Other Areas Involved
	Diameter of CVJ (mm)	Levels Involved		
1	5 mm	C3–T1	none	T8–L3
2	7 mm	C4–T2	C3–4 DDD	none
3	7 mm	C4–7	basilar invagination	none
4	4 mm	C3–6	none	none
5	4 mm	C3–6	none	none

plications after experiencing initial neurological improvement. His lower-extremity strength improved from 2/5 to 3/5 within 1 week postoperatively. All patients continued to improve neurologically as of final follow up 4 to 19 months later, and there was no further progression of the neurological deficit (Table 2).

Discussion

Forestier Disease

Forestier disease or DISH is a relatively common entity as indicated by the 6 to 12% prevalence rate reported in general autopsy series.^{16,22,23} The most widely accepted radiological criteria for FD was proposed by Resnick and Niwayama²² in 1976. They include flowing calcification along anterolateral aspect of at least four contiguous vertebral bodies, relative preservation of intervertebral disc height in affected areas, and absence of apophyseal joint ankylosis and sacroiliac joint sclerosis.^{22,23} It typically affects men in their mid-sixth to seventh decade of life and most frequently affects the lower thoracic spine, causing mid- to low-back pain and stiffness.^{8,16,20,22,23} When the cervical spine is involved, dysphagia is the most common presenting complaint. Nearly 30% of patients describe swallowing difficulty and 10% require surgical intervention.^{3,7,10,11,16} It is unusual to have neurological symptoms associated with FD. In 1995 Goto, et al.,¹² described a case of FD that caused cervical myelopathy and quadriplegia. In this patient a pseudarthrosis developed between the posterior tubercle of the atlas and the spinous process of the axis and caused extradural compression.

In the group of patients in the present report FD-related progressive neurological deficits developed due to the development of a nonrheumatoid retroodontoid pannus.

Retroodontoid Mass

There are various conditions associated with retroodontoid degenerative soft-tissue pannus formation, but FD has not been previously included. The most commonly described cause of retroodontoid pannus formation is RA. Occasionally os odontoidem and, less frequently, pseudogout (periodontoid calcium pyrophosphate dihydrate deposition disease), nonunion of odontoid fractures, retroodontoid disc herniation, and synovial cysts have been described in association with pannus formation as well. These conditions are clearly different pathological entities that can certainly coexist in patients with FD; however, in our series of patients there was no evidence of other coexisting disease. Histopathological examination in our series showed nonneoplastic, degenerative, and

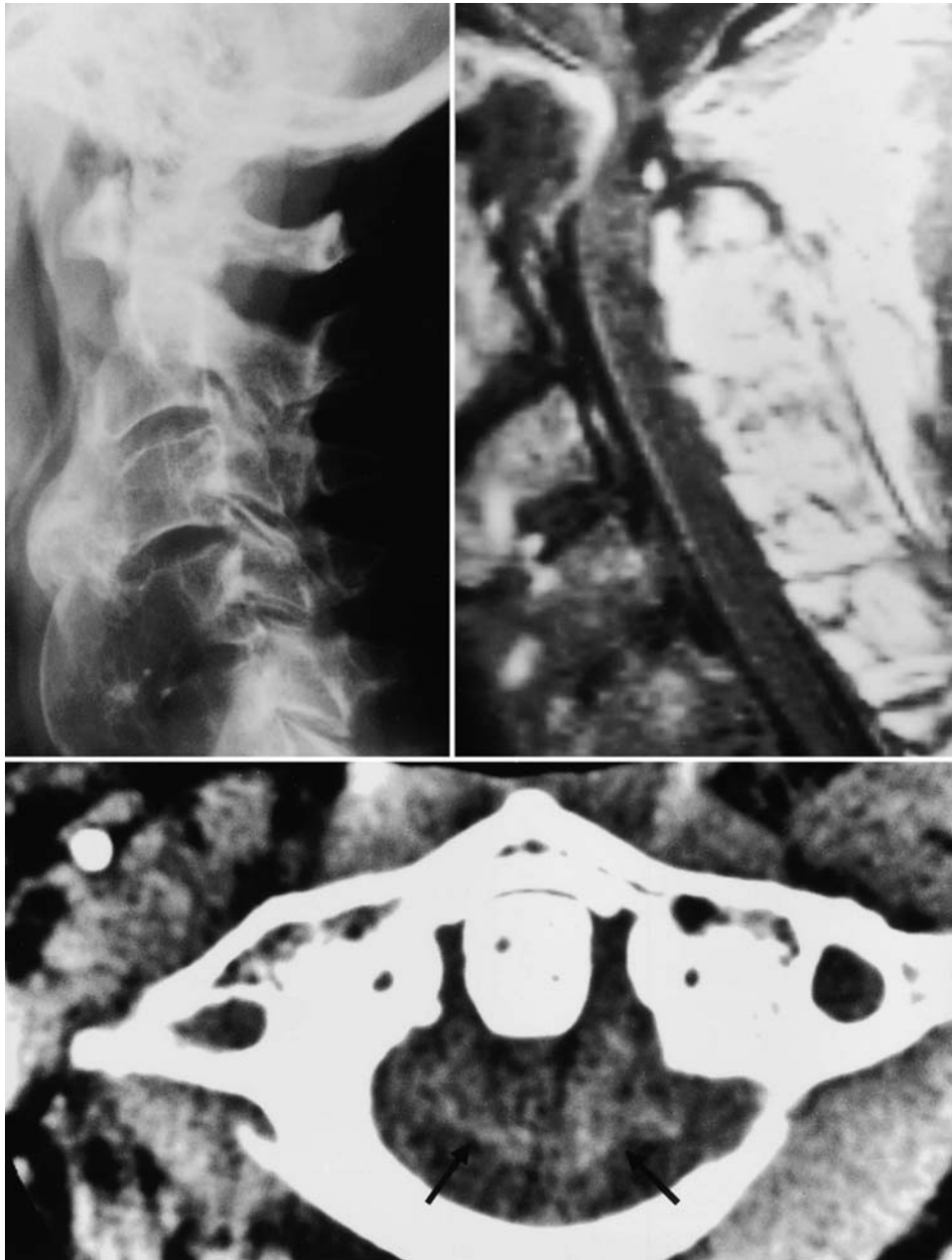

FIG. 1. *Upper Left:* Preoperative radiograph revealing marked calcification of the ALL. *Upper Right:* Preoperative MR image revealing marked cervicomedullary compression. *Lower:* Preoperative axial CT scan demonstrating a retroodontoid soft-tissue mass (*arrows*).

inflammatory tissue. Although the process bears similarity to that in RA, there was no evidence of RA in any of our patients.

Pathophysiology of Mass Formation

The common finding of multilevel fusion of the subaxial cervical spine was demonstrated in all five cases. This fusion coupled with the mobility of the craniovertebral joint complex seems to play a pivotal role in the gradual development of a retroodontoid mass. The occipitoatlantoaxial joint accounts for 45° of flexion and extension and 50% of the rotation in the normal cervical spine,

whereas each subaxial level in the cervical spine contributes between 10 and 20° of flexion and extension.^{18,26} In FD, ALL calcification-induced multilevel subaxial fusion concentrates the mechanical stresses at the atlantoaxial junction. Chronic strain on the supporting ligaments and the surrounding soft tissues, particularly involving the occipitoatlantoaxial complex, results in repeated and continual microtears of the periodontoid ligaments. These stresses, combined with the scarring associated with the ensuing healing process, cause gradual accumulation of degenerative and inflammatory material, which is accompanied by compensatory ligamentous hypertrophy. The

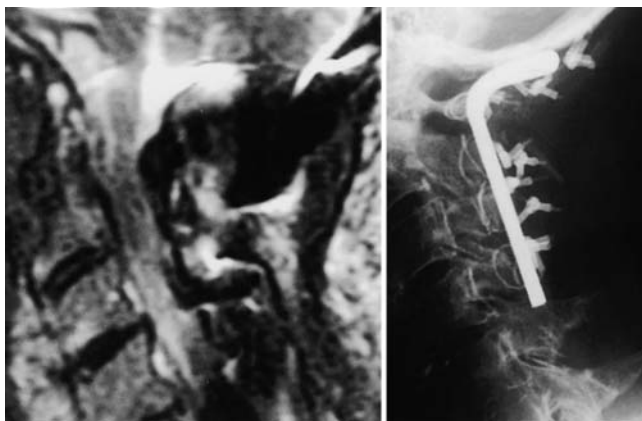


FIG. 2. *Left:* Postoperative MR image revealing decompression of the CVJ. *Right:* Postoperative radiograph obtained after occipitocervical instrumentation and fusion.

theory of ligamentous hypertrophy secondary to increased mechanical stress is not a unique concept and has been well documented to occur in the ligamentum flavum of the lumbar region.^{9,15}

The histopathological findings are likely explained by a series of events beginning with fibrous matrix and eosinophilic degeneration. Subsequently, focal dystrophic calcification and inflammatory neovascularization occur as a result of chronic focal stress. This process is analogous to granulation tissue formation that occurs during scarring.

Perioperative Management

Surgical management is often the only viable option to halt the progressive neurological deficit that develops in these frequently frail and debilitated patients. Grob, et al.,¹³ have shown that posterior fusion alone allows gradual regression of anterior cervicomedullary pannus size in patients with RA. Similarly, a stand-alone posterior fusion in FD patients would most likely yield the same results, leading to pannus involution over a period of several months. This would be feasible in patients with mild or static neurological symptoms, avoiding the potential complications associated with a transoral approach. In patients with severe and rapidly progressive motor symptoms due to spinal cord compression, a transoral approach may be used to achieve an immediate decompression. In four of our five patients severe anterior cervicomedullary compression and MR imaging signal changes were demonstrated, with rapidly progressive myelopathy and quadriplegia. A transoral approach was indicated in these patients to address the severity of the anterior compression directly. Although transoral resection of the mass may directly address the primary problem, the resulting instability requires either a C1–2 fusion or an occipitocervical fusion.⁵ A C1–2 fusion is most likely inadequate because of the potential for failed fusion, particularly in light of the severely altered biomechanics related to the underlying FD. A more definitive occipitocervical fusion appears to be the optimal procedure (A Crockard: Personal communication, April 1997).^{1,2,25} The disadvantages of a longer operative time and marked reduction of neck motion is often justified to prevent a serious neurological complica-

tion, such as the subluxation sustained by the patient in our Case 4.

In one of the four patients who underwent transoral surgery the palate was divided to obtain improved superior exposure. The potential complications of delayed wound healing and aspiration pneumonia should be closely monitored. The risk could be lessened by a 7- to 10-day course of broad-spectrum antibiotic medication and filling the odontoid resection cavity with a fat graft to promote healing and reduce the risk of infection.¹⁴ The risk of aspiration is significant because these patients often have difficulty swallowing postoperatively. In certain situations, preoperative or early postoperative insertion of a gastric feeding tube may decrease the risk of aspiration as well as correct nutritional deficiencies.

Conclusions

Forestier disease most commonly presents in the elderly population, causing dysphagia, and FD-associated neurological deficits are rare. The development of a soft-tissue retroodontoid hypertrophic pannus in association with progressive neurological deficit is caused by altered biomechanics at the atlantoaxial junction. The typical degenerative hypertrophy of the soft tissues in the retroodontoid region in FD patients is distinctly different from other well-known causes. There should be a heightened suspicion for CVJ lesions of this nature in patients with FD who present with cervical myelopathy.

References

1. An HS, Simpson JM (eds): **Surgery of the Cervical Spine**. Baltimore: Williams & Wilkins, 1994
2. Apostolides PJ, Dickman C, Golfinos JG, et al: Threaded steinmann pin fusion of the craniovertebral junction. **Spine 21**: 1630–1637, 1996
3. Chen TY, Lui TN: Retrodental fibrocartilaginous mass. Report of a case. **Spine 22**:920–923, 1997
4. Clark CR: Rheumatoid involvement of the cervical spine. An overview. **Spine 19**:2257–2258, 1994
5. Dickman CA, Crawford NR, Brantley AG, et al: Biomechanical effects of transoral odontoidectomy. **Neurosurgery 36**: 1146–1153, 1995
6. Ditunno JF, Young W, Donovan WH, et al: The international standards booklet for neurological and functional classification of spinal cord injury. American Spinal Injury Association. **Paraplegia 32**:70–80, 1994
7. Eviatar E, Harell M: Diffuse idiopathic skeletal hyperostosis with dysphagia (a review). **J Laryngol Otol 101**:627–632, 1987
8. Forestier J, Rotes-Querol J: Senile ankylosing hyperostosis of the spine. **Ann Rheumat Dis 9**:321–330, 1950
9. Fukuyama S, Nakamura T, Ikeda T, et al: The effect of mechanical stress on hypertrophy of the lumbar ligamentum flavum. **J Spinal Disord 8**:126–130, 1995
10. Gamache FW Jr, Voorhies RM: Hypertrophic cervical osteophytes causing dysphagia. A review. **J Neurosurg 53**:338–344, 1980
11. Goffin J, Van Calenbergh F: Forestier's disease. **J Neurosurg 85**:524–525, 1996
12. Goto S, Tanno T, Moriya H: Cervical myelopathy caused by pseudoarthrosis between the atlas and axis associated with diffuse idiopathic skeletal hyperostosis. **Spine 20**:2572–2575, 1995
13. Grob D, Wursch R, Grauer W, et al: Atlantoaxial fusion and

- retrodental pannus in rheumatoid arthritis. **Spine** **22**: 1580–1584, 1997
14. Kim K, Johnson J, Masciopinto J, et al: Anterior transoral surgical techniques, in An H, Cotler J (eds): **Spinal Instrumentation**, ed 2. Philadelphia: Lippincott, Williams and Wilkins, 1999
 15. Markolf KL, Morris JM: The structural components of the intervertebral disc. A study of their contributions to the ability of the disc to withstand compressive forces. **J Bone Joint Surg (Am)** **56**:675–687, 1974
 16. McCafferty RR, Harrison MJ, Tamas LB, et al: Ossification of the anterior longitudinal ligament and Forestier's disease: an analysis of seven cases. **J Neurosurg** **83**:13–17, 1995
 17. Menezes AH: **Normal and Abnormal Development of the Craniocervical Junction. Neurosurgery: The Scientific Basis of Clinical Practice**. London: Blackwell Scientific Publications, 1992, pp 63–83
 18. Panjabi MM, Vasavada A, White AA: Cervical spine biomechanics. **Semin Spine Surg** **5**:10–16, 1993
 19. Pollack IF, Welch W, Jacobs GB, et al: Frameless stereotactic guidance. An intraoperative adjunct in the transoral approach for ventral cervicomedullary junction decompression. **Spine** **20**:216–220, 1995
 20. Quagliano PV, Hayes CW, Palmer WE: Vertebral pseudoarthrosis associated with diffuse idiopathic skeletal hyperostosis. **Skeletal Radiol** **23**:353–355, 1994
 21. Reisner A, Stiles RG, Tindall SC: Diffuse idiopathic skeletal hyperostosis causing acute thoracic myelopathy: a case report and discussion. **Neurosurgery** **26**:507–511, 1990
 22. Resnick D, Niwayama G: **Diagnosis of Bone and Joint Disorders**. Philadelphia: WB Saunders, 1988, pp 1562–1602
 23. Resnick D, Niwayama G: Radiographic and pathologic features of spinal involvement in diffuse idiopathic skeletal hyperostosis (DISH). **Radiology** **119**:559–568, 1976
 24. Stechison MT, Tator CH: Cervical myelopathy in diffuse idiopathic skeletal hyperostosis. Case report. **J Neurosurg** **73**: 279–282, 1990
 25. Suzuki K, Ishida Y, Ohmori K: Long term follow-up of diffuse idiopathic skeletal hyperostosis in the cervical spine. Analysis of progression of ossification. **Neuroradiology** **33**:427–431, 1991
 26. White AA, Panjabi MM: **Clinical Biomechanics of the Spine**, ed 2. Philadelphia: JB Lippincott, 1990
 27. Zapletal J, Hekster RE, Straver JS, et al: Association of transverse ligament calcification with anterior atlanto-odontoid osteoarthritis: CT findings. **Neuroradiology** **37**:667–669, 1995
 28. Zeidman SM, Ducker TB: Rheumatoid arthritis. Neuroanatomy, compression, and grading of deficits. **Spine** **19**:2259–2266, 1994
 29. Zunkeler B, Schelper R, Menezes A: Periodontoid calcium pyrophosphate dihydrate deposition disease: "pseudogout" mass lesions of the craniocervical junction. **J Neurosurg** **85**: 803–809, 1996.

Manuscript received March 14, 2001.

Accepted in final form November 15, 2001.

Address reprint requests to: J. Patrick Johnson, M.D., Cedars-Sinai Institute for Spinal Disorders, 444 South San Vicente Boulevard, Suite 800, Los Angeles, California 90048. email: johnsonjp@cshs.org.