

Sagittal alignment and the Bryan cervical artificial disc

J. PATRICK JOHNSON, M.D., CARL LAURYSSSEN, M.D., HELEN O. CAMBRON, R.N., N.P., ROBERT PASHMAN, M.D., JOHN J. REGAN, M.D., NEEL ANAND, M.D., AND ROBERT BRAY, M.D.

Cedars-Sinai Institute for Spinal Disorders, Los Angeles, California

Object. The authors evaluated cervical spine radiographs to determine sagittal alignment in patients who underwent one- or two-level arthroplasty with the Bryan cervical artificial disc prosthesis.

Methods. The curvature of the surgically treated spinal segments and the overall curvature of the cervical spine were evaluated in 13 patients who underwent 16 cervical arthroplasty device placements. Preoperative and postoperative lateral radiographs were reviewed and compared using standardized techniques for measuring spinal curvature.

Patients who underwent a single-level cervical arthroplasty had a 4.7° mean reduction ($p < 0.05$) in lordosis after cervical artificial disc replacement. The three patients who underwent two-level cervical arthroplasty had no significant changes in the sagittal alignment.

Conclusions. Patients who underwent arthroplasty with a Bryan cervical artificial disc had a focal loss of lordosis (that is, kyphosis) at the treated levels after single-level procedures. Nevertheless, there was no significant change in the overall sagittal curvature of the cervical spine after single-level artificial disc replacements. The patients who underwent two-level artificial disc placement had no significant changes in lordosis at the treated levels or in the overall curvature. The likely source of this outcome appears to be the endplate milling procedures that reorient the vertebral endplates.

KEY WORDS • artificial disc • kyphosis • sagittal spinal balance

Arthroplasty performed with artificial cervical discs has gained significant attention recently as an alternative to traditional arthrodesis that can be used to maintain, preserve, and restore mobility and function in cervical spinal segments.^{3,5,6,10,11,14,16,19–21} The importance placed on proper alignment in spinal reconstructive procedures has evolved through experience to recognize that restoration or maintenance of a normal cervical lordotic curvature is essential.^{9,15,17} Patients with cervical sagittal malalignment may increase the potential for pain and degenerative changes to develop at treated and adjacent segmental levels, which could also accelerate these degenerative changes.^{8,15,21} Consequently, the ideal cervical spinal arthroplasty device and procedure would restore normal lordotic sagittal alignment as well as maintain segmental mobility. It has been observed that patients undergoing arthroplasty with the Bryan cervical disc suffer a segmental loss of lordosis (that is, kyphosis) at the treated level. The purpose of this study was to evaluate the sagittal alignment of individual segments at the surgically treated level and the overall sagittal alignment of the cervical spine in patients undergoing arthroplasty.

CLINICAL MATERIAL AND METHODS

The study group consisted of 13 patients who underwent spinal arthroplasty with placement of the Bryan cervical artificial disc prosthesis. The C4–5 level was treated in three patients, C5–6 and C6–7 in six each, and C7–T1

was treated in one patient. The pre- and postoperative, neutral-position, lateral radiographs were evaluated for sagittal alignment.

There were 10 women and three men in the study group whose mean age was 42.2 years (range 27–54 years). These patients had symptomatic degenerative cervical disc disease that would usually be treated with an anterior cervical discectomy and fusion procedure. They underwent an anterior cervical discectomy and cervical arthroplasty with placement of the Bryan cervical artificial disc prosthesis (Medtronic, Inc., Memphis, TN) according to a standardized procedure that involves a precision placement technique in which a frame with a jig is fastened to the ventral aspect of the surgically treated cervical spine.

Patients included in the study were selected from the US Investigational Device Exemption trial at our institution with Institutional Review Board approval, and we also included patients who underwent cervical disc arthroplasty outside the US and we followed them postoperatively. Patients from our institution were part of an ongoing randomized study in which they underwent either disc arthroplasty or a conventional anterior cervical discectomy and fusion with an allograft and plate fusion procedure (control group). The patients treated outside the US were provided with courtesy postoperative care and evaluation by the surgeon who had performed the operation.

The routine follow-up examination included general and neurological evaluations and lateral cervical radiographs to assess the cervical spine reconstruction procedure.

ture. The radiographic parameters evaluated included the treated segments where the Bryan disc was placed and the overall curvature of the cervical spine. To ascertain the cervical angles measured to evaluate sagittal alignment, we used the techniques^{7,18} in which the tangent to the posterior body line of the treated segments (Fig. 1 *left*) is calculated and the overall cervical curvature is determined from the tangent of the posterior body line of C-2 and C-7 (Fig. 1 *right*). A kyphotic curvature is indicated by a positive value or by lordotic curvature and a negative value. Standard statistical methods were applied using a Student t-test to analyze the difference, and statistical significance was determined using commercially available software.

RESULTS

There were 13 patients in the study group, in whom 16 treated levels were evaluated. There were 10 patients who underwent a single-level and three who underwent a two-level cervical arthroplasty. Of the latter group, two patients had a two-level cervical arthroplasty at contiguous levels and one had two levels treated at distal ends of a previous fusion. One patient underwent a single-level arthroplasty adjacent to a previous two-level fusion procedure.

Spinal Curvature and Single-Level Bryan Artificial Disc Placement

The mean preoperative cervical curvature at the level of the disc to be treated in the single-level arthroplasty group was +1° and the postoperative curvature was -3.7°, which represented a statistically significant mean loss of 4.7° of lordosis (p < 0.05, Table 1). The overall preoperative cervical lordosis (that is, C2-7) was +10.7°, and postoperatively it was +8°, or a loss of 2.7°, which was not statistically significant (p > 0.05). A clinical case that was closely consistent with this observation is depicted in Fig. 2.

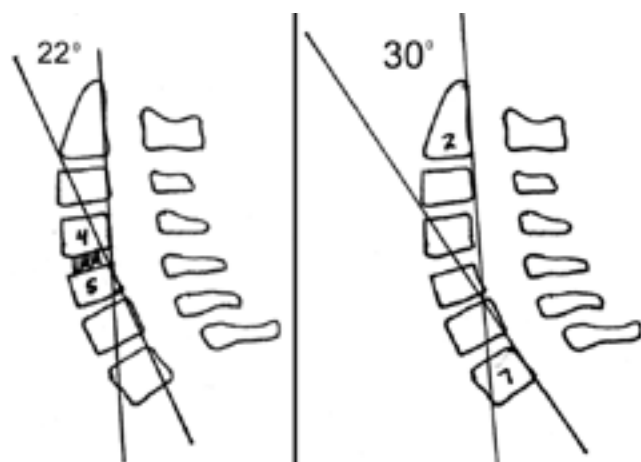


Fig. 1. *Left*: Illustrations showing the method used to determine specific cervical curvature at two adjacent vertebral levels (22° at C4-5 in this panel). *Right*: Illustration showing the method used to determine the overall cervical curvature between C-2 and C-7 (30° in this panel). Numbers designate cervical segments.

TABLE 1

Sagittal alignment (°) after single-level Bryan disc replacement

Level	At Op Level			Overall Cervical Curvature		
	Preop	Postop	Change	Preop	Postop	Change
C4-5	+9	-4	-13	+8	+1	-7
C4-5	-15	-14	+1	+8	+7	-1
C5-6	+6	0	-6	+25	+12	-13
C5-6	0	-5	-5	+20	+15	-5
C5-6	-1	-11	-10	+10	+15	-5
C5-6	+2	+8	+6	+37	+29	-8
C6-7	0	-5	-5	-5	-3	+2
C6-7	-4	-6	-2	+6	+18	+12
C6-7	+1	-4	-5	+12	+6	-6
C6-7	+6	0	-6	+8	-19	-27
mean	+1.0	-3.7	-4.7*	+10.7	+8.0	-2.7

* Significant difference (p < 0.05) determined using the Student t-test.

Spinal Curvature and Two-Level Bryan Artificial Disc Replacement

The mean preoperative cervical curvature at the treated levels in the patients undergoing two-level arthroplasty was -2.5° and the postoperative curvature was -2.3°, resulting in no apparent changes. The overall preoperative cervical curvature in the patients who underwent two-level arthroplasty was +4.7° and the lordosis increased to +7.3°, for an increase in lordosis to +2.6°; none of these was statistically significant (Table 2). A clinical case of a two-level arthroplasty is depicted in Fig. 3.

DISCUSSION

Overview of the Procedure

Sagittal balance in the spinal column has become an important and recognized goal in any spinal reconstructive surgical procedure. The normal anatomical configuration of the spinal column has four primary, well-known curves that include cervical and lumbar lordosis and thoracic and sacral kyphosis. The normal cervical spine has a lordosis angle that ranges from 10 to 40° and has a wide range of

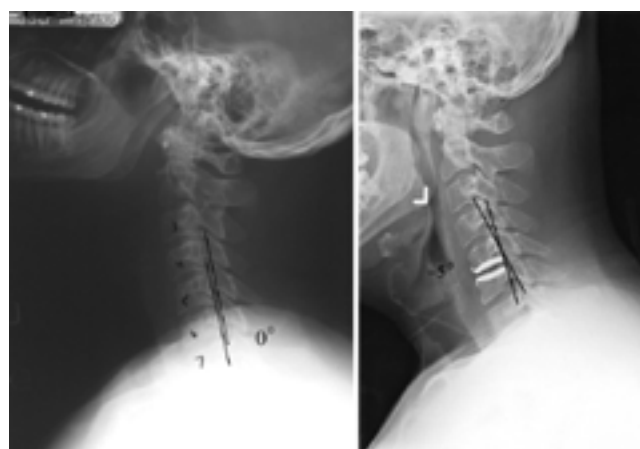

Fig. 2. Preoperative (*left*) and postoperative (*right*) lateral cervical radiographs of a C5-6 Bryan disc arthroplasty showing changes in sagittal alignment from 0 to -5° at the treated segment.

Sagittal alignment and the Bryan cervical artificial disc

TABLE 2
Sagittal alignment (°) after two-level Bryan disc replacement

Level	At Op Levels			Overall Cervical Curvature		
	Preop	Postop	Change	Preop	Postop	Change
C5-6 & C6-7	-12	-12	0	+8	+10	+2
	+6	+9	+3			
C5-6 & C6-7	-1	-7	-6	+6	+5	-1
	-2	+6	+8			
C4-5 & C7-T1	-1	-5	-4	0	+7	+7
	-5	-5	0			
mean*	-2.5	-2.3	+0.2	+4.7	+7.3	+2.7

* No differences were statistically significant.

individual variability.^{12,13} There is also a well-known variability of angulation between adjacent vertebral segments, and a single abnormal segment within the spinal column can have an adverse effect on the clinical symptoms.

Previous spinal arthrodesis reconstruction procedures in the cervical and lumbar regions have often resulted in loss of lordotic curvature, which is now recognized as a less than desirable outcome.^{1,9} Indeed, some of these patients have clinically significant problems relating to iatrogenically produced loss of lordosis at treated segments, and a significant body of knowledge has been generated from the surgical revision procedures performed to correct these abnormalities.^{8,9,15} It is now generally recognized that any surgical reconstructive procedure in the cervical and lumbar spine should have as one of its major goals either the maintenance or restoration of appropriate lordotic curvature.^{9,15}

Rationale for Cervical Arthroplasty

Degenerative cervical disc disease causing radiculopa-

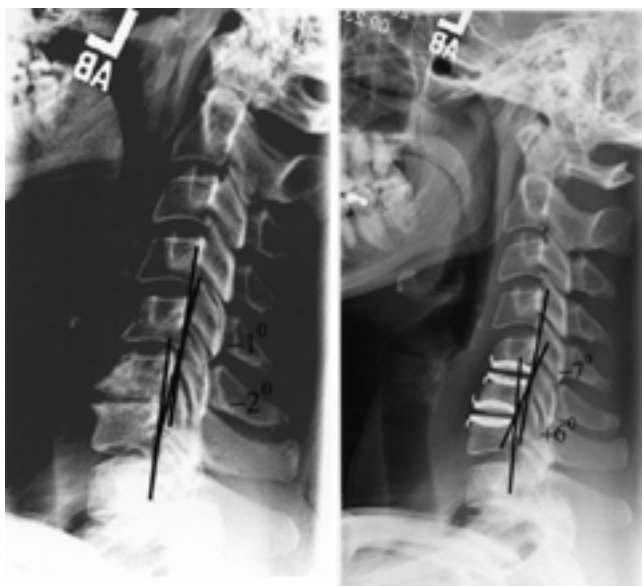


Fig. 3. Preoperative (left) and postoperative (right) lateral cervical radiographs of a two-level C5-6 and C6-7 Bryan disc arthroplasty revealing minimal changes in sagittal alignment.

thy or myelopathy has been successfully treated with arthrodesis for nearly 50 years. The anterior cervical discectomy procedure has become a standardized operation that has matured significantly in recent years, with predictable results and outcomes. Despite the high rate of satisfactory outcomes, degenerative changes can occur adjacent to the treated segment if enough time elapses.

The interest in cervical arthroplasty has evolved from many years of experience and there is recognition that degenerative changes adjacent to an arthrodesis will occur predictably; several articles that are widely cited have established a basis for this observation.^{3,8,10,19} Additionally, there has been a general observation that any malalignment in a particular spinal segment may accelerate degenerative changes.^{8,9,15} Subsequently, an arthrodesis in combination with spinal malalignment may produce even greater adjacent-segment stresses and subsequent acceleration of degenerative changes, thus stimulating further interest in procedures and techniques that maintain both motion and sagittal alignment.

Anecdotally, all spinal surgeons who have been in practice for many years will eventually see patients in whom adjacent-segment degenerative changes have developed and will recognize that these are indeed multifactorial processes. The number of patients with accelerated degeneration from multilevel arthrodesis has not been clearly established but this phenomenon is to be expected. Subsequent to degeneration, the role for one-level (or more) arthroplasty procedures as described in this study is presently a small one. Nevertheless, the need for these procedures may be a better indication for arthroplasty; this need is logical and will increase over time.

Sagittal Alignment in Cervical Arthroplasty

Although the major goal of cervical arthroplasty is the maintenance of motion, there has been little written in the current literature regarding the effects of these procedures on spinal alignment. In our study we have demonstrated that the focal symptomatic segment within the cervical spine is usually kyphotic because of loss of disc height. We have also shown that cervical arthroplasty with the Bryan disc, with its current configuration and placement techniques, is limited in its ability to produce significant correction of the loss of height and restoration of lordotic angulation.

This study is indeed limited to the radiographic evaluation of sagittal alignment alone and is not correlated with clinical symptoms, which is a necessary next step. Nevertheless, because essentially all patients have experienced a loss of lordosis of nearly 5° after the arthroplasty procedure, there is no direct comparison. Potentially, this variable can be compared as an independent variable to other cervical arthroplasty devices to determine if this is an important factor. Because sagittal alignment is considered to be an important factor in arthrodesis, we would expect that it is also an important variable in arthroplasty; however, the preservation of mobility in all spinal segments with the latter procedure may allow for some postural compensation. There was no significant change in the patients undergoing two-level arthroplasty, but the small number of patients limits our ability to draw any significant conclusions.

The role of endplate milling in the Bryan procedure has not resulted in significant settling in previous studies, but clearly more longitudinal investigations are needed.^{2,4,6,14} Even if no settling occurs, the amount of milling in the procedure may require some modification to reduce the amount of endplate removed, thus reducing the loss of vertebral height and subsequent loss of lordosis that occurs with the operation. Further refinement of the milling procedure directed at performing a lordotic milling may also reproduce the desired lordotic angulation. Another possibility is some lordotic modification of the arthroplasty device to recreate the desired lordotic curvature.

CONCLUSIONS

Cervical disc arthroplasty has the potential to allow surgeons to treat patients with symptomatic degenerative disc disease with a motion-preserving procedure. Among the many technical issues involving the device's design and placement is restoration and maintenance of sagittal balance. The Bryan disc placement and vertebral endplate milling procedures may require revisions to optimize the function of this unique arthroplasty implant.

Disclosure

The authors are coinvestigators in the Bryan Cervical Artificial Disc Study sponsored by Medtronic Sofamor Danek, the manufacturer of the prosthesis, and have a financial interest in the device.

References

- Aita I, Wadano Y, Yabuki T: Curvature and range of motion of the cervical spine after laminoplasty. **J Bone Joint Surg Am** **82**:1743–1748, 2000
- Bao QB, McCullen GM, Higham PA, et al: The artificial disc: theory, design and materials. **Biomaterials** **17**:1157–1167, 1996
- Cinotti G, David T, Postacchini F: Results of disc prosthesis after a minimum follow-up period of 2 years. **Spine** **21**:995–1000, 1996
- Eijkelkamp MF, van Donkelaar CC, Veldhuizen AG, et al: Requirements for an artificial intervertebral disc. **Int J Artif Organs** **24**:311–321, 2001
- Enker P, Steffee A, McMillin C, et al: Artificial disc replacement. Preliminary report with a 3-year minimum follow-up. **Spine** **18**:1061–1070, 1993
- Goffin J, Casey A, Kehr P, et al: Preliminary clinical experience with the Bryan Cervical Disc Prosthesis. **Neurosurgery** **51**:840–847, 2002
- Gore DR, Sepic SB, Gardner GM: Roentgenographic findings of the cervical spine in asymptomatic people. **Spine** **11**:521–524, 1986
- Hilibrand AS, Carlson GD, Palumbo MA, et al: Radiculopathy and myelopathy at segments adjacent to the site of a previous anterior cervical arthrodesis. **J Bone Joint Surg Am** **81**:519–528, 1999
- Katsuura A, Hukuda S, Saruhashi Y, et al: Kyphotic malalignment after anterior cervical fusion is one of the factors promoting the degenerative process in adjacent intervertebral levels. **Eur Spine J** **10**:320–324, 2001
- Kim WJ, Lee SH, Kim SS, et al: Treatment of juxtafusal degeneration with artificial disc replacement (ADR): preliminary results of an ongoing prospective study. **J Spinal Disord Tech** **16**:390–397, 2003
- Kotani Y, Abumi K, Shikinami Y, et al: Two-year observation of artificial intervertebral disc replacement: results after supplemental ultra-high strength bioresorbable spinal stabilization. **J Neurosurg Spine** **10**:337–342, 2004
- Loder RT: Profiles of the cervical, thoracic, and lumbosacral spine in children and adolescents with lumbosacral spondylolisthesis. **J Spinal Disord** **14**:465–471, 2001
- Penning L: Normal movements of the cervical spine. **AJR** **130**:317–326, 1978
- Pickett GE, Duggal N: Artificial disc insertion following anterior cervical discectomy. **Can J Neurol Sci** **30**:278–283, 2003
- Rajshekhkar V, Arunkumar MJ, Kumar SS: Changes in cervical spine curvature after uninstrumented one- and two-level corpectomy in patients with spondylotic myelopathy. **Neurosurg** **52**:799–805, 2003
- Sekhon LH: Cervical arthroplasty in the management of spondylotic myelopathy. **J Spinal Disord Tech** **16**:307–313, 2003
- Takeshima T, Omokawa S, Takaoka T, et al: Sagittal alignment of cervical flexion and extension: lateral radiographic analysis. **Spine** **27**:E348–E355, 2002
- Thometz JG, Lamdan R, Liu XC, et al: Relationship between Quantec measurement and Cobb angle in patients with idiopathic scoliosis. **J Pediatr Orthop** **20**:512–516, 2000
- Wigfield C, Gill S, Nelson R, et al: Influence of an artificial cervical joint compared with fusion on adjacent-level motion in the treatment of degenerative cervical disc disease. **J Neurosurg Spine** **96**:17–21, 2002
- Wigfield CC, Gill SS, Nelson RJ, et al: The new Frenchay artificial cervical joint: results from a two-year pilot study. **Spine** **27**:2446–2452, 2002
- Wigfield CC, Skrzypiec D, Jackowski A, et al: Internal stress distribution in cervical intervertebral discs: the influence of an artificial cervical joint and simulated anterior interbody fusion. **J Spinal Disord Tech** **16**:441–449, 2003

Manuscript received September 24, 2004.

Accepted in final form October 27, 2004.

Address reprint requests to: J. Patrick Johnson, M.D., Cedars-Sinai Institute for Spinal Disorders, 444 South San Vicente Boulevard, Suite 800, Los Angeles, California 90048. email: johnsonjp@cshs.org.